

Krešimir Pavelić · Mirko Hadžija · Ljiljana Bedrica
Jasminka Pavelić · Ivan Đikić · Maša Katić
Marijeta Kralj · Maja Herak Bosnar
Sanja Kapitanović · Marija Poljak-Blaži
Šimun Križanac · Ranko Stojković · Mislav Jurin
Boris Subotić · Miroslav Čolić

Natural zeolite clinoptilolite: new adjuvant in anticancer therapy

Received: 17 April 2000 / Accepted: 15 October 2000 / Published online: 24 January 2001
© Springer-Verlag 2001

Abstract Natural silicate materials, including zeolite clinoptilolite, have been shown to exhibit diverse biological activities and have been used successfully as a vaccine adjuvant and for the treatment of diarrhea. We report a novel use of finely ground clinoptilolite as a potential adjuvant in anticancer therapy. Clinoptilolite treatment of mice and dogs suffering from a variety of tumor types led to improvement in the overall health status, prolongation of life-span, and decrease in tumors size. Local application of clinoptilolite to skin cancers of dogs effectively reduced tumor formation and growth. In addition, toxicology studies on mice and rats demonstrated that the treatment does not have negative effects. In vitro tissue culture studies showed that finely ground clinoptilolite inhibits protein kinase B (c-Akt), induces expression of p21^{WAF1/CIP1} and p27^{KIP1} tumor suppressor proteins, and blocks cell growth in several cancer cell lines. These data indicate that clinoptilolite treatment might affect cancer growth by attenuating survival signals and inducing tumor suppressor genes in treated cells.

Keywords Clinoptilolite · Adjuvant · Anticancer · Treatment



KREŠIMIR PAVELIĆ received his M.D./Ph.D. degree in medicine and experimental oncology from the University of Zagreb, Croatia. He received research fellowship at the RPMI in Buffalo, N.Y., University of Cincinnati, Ohio, and Fullbright fellowship at the Mayo Clinic, Rochester, Minn., USA. He is director of the Division of Molecular Medicine at Ruđer Bošković Institute and Director of the National Cancer Research Program of the Republic of Croatia. Dr. Pavelić is also Professor of Molecular Biology at the Department of Pharmacy and Biochemistry at the University of Zagreb. His research interests include molecular medicine, particularly cancer genetic.



MIROSLAV ČOLIĆ received his Ph.D. in applied surface chemistry with minors in molecular biology and biophysics from the University of California at Berkeley, USA. He is presently Vice President of the Research and Development Division, Molecutec Corporation, Goleta, California. His research interests include free radicals chemistry and biology, environmental chemistry, biomedical effects of dietetic products, and small molecules drug discovery.

K. Pavelić (✉) · M. Hadžija · J. Pavelić · M. Katić · M. Kralj
M.H. Bosnar · S. Kapitanović · M. Poljak-Blaži · R. Stojković
M. Jurin · B. Subotić
Ruđer Bošković Institute, Division of Molecular Medicine and
Division of Material Chemistry, Bijenička 54, Zagreb, Croatia
e-mail: pavelic@rudjer.irb.hr
Tel.: +3851-46-80094, Fax: +3851-46-80094

L. Bedrica
Veterinary Faculty, University of Zagreb, Heinzelova 55,
10001 Zagreb, Croatia

I. Đikić
Ludwig Institute for Cancer Research, Biomedical Center,
Husargatan 3, Uppsala, Sweden

Š. Križanac
Institute of Pathology, Faculty of Medicine, University of Zagreb,
Šalata 11, Zagreb, Croatia

M. Čolić
Molecular Technologies Inc., 6512 Segovia, Goleta, CA 93117, USA

Abbreviations *EGF*: Epidermal growth factor · *FBS*: Fetal bovine serum · *MAPK*: Mitogen-activated protein kinases · *PDGF*: Platelet-derived growth factor · *SDS*: Sodium dodecyl sulfate

Introduction

Zeolites are hydrated natural and synthetic microporous crystals with well-defined structures containing AlO_4 and SiO_4 tetrahedra linked through the common oxygen atoms [1]. Zeolites have been extensively used in various industrial applications based on their properties to act as catalysts, ion exchangers, adsorbents, and detergent builders [2, 3, 4, 5, 6]. It is also known that silicates and aluminosilicates possess biological activity, either positive or negative. Talc and silica have been used in skin care for many decades, while well defined structures and catalytic activity make aluminosilicates an attractive model system for protein and enzyme mimetics [7]. Recent results have also demonstrated that natural, biologically nontoxic clinoptilolite from Cuba deposits is very effective as glucose adsorbent, and this has been suggested as a potential medication for individuals suffering from diabetes mellitus [8].

The best known positive biological activity of natural clinoptilolite is its action as antidiarrheal drug (see [9] and references therein). Clinoptilolite lowers the incidence of death and sickness (diarrheal syndrome) produced by intestinal diseases in swine, rats, and calves (see [9] and references therein). Based on these results a comprehensive study was carried out on antidiarrheal drugs based on natural clinoptilolite as an active material, in the therapy of acute diarrheal diseases in humans [9]. The research led to approval of the antidiarrheal drug Enterex for use in humans. In addition, accumulating evidence has indicated that zeolites play an important role in regulating the immune system. Ueki et al. [10] and Aikoh et al. [11] have reported that silica, silicates, and aluminosilicates act as nonspecific immunostimulators similarly to superantigens. Superantigens are a class of immunostimulatory and disease-causing proteins of bacterial and viral origin with the ability to activate relatively large fractions (5–20%) of the T cell population. Activation requires simultaneous interaction of the superantigens with V β domain of T cell receptor and with major histocompatibility complex class II molecules on the surface of antigen presenting cells [10]. Pro-inflammatory macrophages, which belong to class II MHC antigen-presenting cells, are activated by fibrogenic silicate particulates [12, 13, 14, 15]. Indeed, experiments carried out by Ueki and coworkers [10] have shown that removal of MHC class II DP/DR positive cells results in a lack of macrophage stimulation by asbestos.

Direct interaction of silicate particles with cells other than lymphocytes has also been identified and described. It seems that mineral particles can trigger alterations in gene expression by initiating signaling events upstream

of gene transactivation [16]. Exposure of cells to silicate particles has been shown to lead to activation of mitogen-activated protein kinases (MAPK), protein kinase C, and stress-activated protein kinases [17]. Important transcription factors such as activator protein 1 and nuclear factor κB are also activated, and expression of pro-inflammatory cytokines such as interleukin 1 α , interleukin 6, and tumor necrosis factor α is enhanced [18]. Modifications in receptor activation kinetics or activity of integrins may be responsible for the observed behavior. Alternatively, particles engulfed by phagocytosis have been reported to stimulate production of reactive oxygen species [19]. It was recently shown that redox regulation of gene expression is a general phenomenon in most cells.

The above knowledge of zeolites and other silicates led us to test the biological activity of natural clinoptilolite. Mechanical treatment of natural clinoptilolite was used to produce small-sized particles (MZ) that were tested for possible toxicity and anticancer activity in vivo. Here we provide evidence that orally administered natural clinoptilolite is nontoxic and useful in cancer treatment in animal models. Additional in vitro tissue culture experiments with various cancer cell lines indicated that MZ treatment modifies intracellular signaling pathways leading to inhibition of survival signals and induction of tumor suppressor genes.

Materials and methods

Natural clinoptilolite

The fine powder of natural clinoptilolite was obtained by tribomechanical micronization. Chemical composition of the MZ was determined by the atomic absorption spectroscopy. Qualitative and quantitative phase analyses of the MZ were performed by powder X-ray diffractometry using a Siemens 5000D diffractometer with $\text{CuK}\alpha$ radiation in the region 2 θ –4–80°. Thermogravimetric and differential thermogravimetric analysis of the MZ was performed using a TA 4000 System (Mettler-Toledo) apparatus. The heating rate was 10 K/min in nitrogen atmosphere. Particle size distribution curves of the MZ were taken by a Mastersize XLB (Malvern) laser light-scattering particle-size analyzer.

Cell lines and proliferation assay

Effect of MZ on in vitro cell proliferation was studied on several human cell lines: diploid fibroblasts (Hef522), cervical carcinoma (HeLa), colon carcinomas (CaCo-2, HT-29, and SW 620), mammary carcinomas (MCF-7 and SkBr-3), and one mouse fibrosarcoma cell line. The cells were maintained by culturing in Dulbecco's modified Eagle's medium supplemented with 10% fetal bovine serum (FBS), 2 mM L-glutamine, 100 U/ml penicillin, and 100 $\mu\text{g}/\text{ml}$ streptomycin in a humidified atmosphere with 5% CO_2 at 37°C. For the purpose of proliferation assay experiments the cells were plated at a concentration of 1×10^4 cells/ml onto 96-microwell plates (200 $\mu\text{l}/\text{well}$). After overnight incubation the standard medium was replaced with the medium which was pretreated with either 0.5, 5, or 50 mg/ml MZ. For this purpose the medium and MZ were mixed, and after 18 h of shaking MZ was pelleted by centrifugation (5000 g for 10 min).

The cells were then incubated for additional 72 h, when cell viability (cell growth) was measured using MTT assay which detects dehydrogenase activity in viable cells. For this purpose the medium was discarded, and MTT was added to each well at con-

centration of 20 µg/40 µl. After 4 h of incubation at 37°C the precipitates were dissolved in 160 µl DMSO. The absorbance was measured on an enzyme-linked immunosorbent assay reader at 570 nm. The cell proliferation is expressed as a percentage of absorbance, recorded in cell line treated with particular concentration of MZ, in relation to the absorbance of control, nontreated, cells which was expressed as 100%.

Analysis of p21^{WAF1/CIP1} and p27^{KIP1}

Experiments with p21^{WAF1/CIP1} and p27^{KIP1} were carried out on human adenocarcinoma (CaCo-2) and human cervical carcinoma (HeLa) cell lines. The cells, originally grown in tissue culture flasks, were collected and seeded onto glass slides. After 24 h the medium was replaced either with the fresh standard medium (control cells) or with the medium pretreated with 50 mg/ml MZ. After 72 h of incubation the cells were washed with PBS and fixed in methanol with 3% hydrogen peroxide (Kemika, Zagreb, Croatia).

Proteins, p21^{WAF1/CIP1} and p27^{KIP1}, expression was analyzed immunocytochemically. Nonspecific binding was blocked by applying normal rabbit serum (1:10) for 30 min. Primary antibodies p21 (5 µg/ml, PharMingen) and p27 (2 µg/ml, Transduction Laboratories) were allowed to bind overnight at 4°C. Slides were washed three times in PBS. Secondary antibody (rabbit anti-mouse; Dako, Denmark) was applied for 1 h at room temperature. Finally, peroxidase-antiperoxidase (Dako) conjugate diluted 1:100 in PBS was applied for 1 h at room temperature. After washing with PBS the slides were stained with 0.025% diaminobenzidine tetrahydrochloride (Sigma) containing 4% H₂O₂ for 7 min and counterstained with hematoxylin for 30 s. The slides were analyzed with a light microscope (Olympus). The level of nonspecific background staining was established for each measurement using control cells processed in the same way but without exposure to the primary antibody.

The concentration of antigen was assessed by estimating the relative visual intensity of a chromogenic label, and the results are expressed on a three-point scale as follows: -, negative staining; +, weak staining and ++, moderate staining.

Biochemical studies of signaling pathways

The following were used: epidermal growth factor (EGF; Intergen), platelet-derived growth factor (PDGF) BB (Amgen), protein ladder markers (10–200 kDa; Life Technologies), leupeptin and a miniprotease inhibitor kit (Boehringer-Mannheim), Pefabloc (Fluka), aprotinin (Trasylol, Bayer), and nitrocellulose membranes (Millipore). Affinity-purified rabbit polyclonal anti-Akt, anti-pAkt, anti-JNK, anti-pJNK and anti-pERK2 (MAPK) antibodies were purchased from New England Biolabs. The rabbit polyclonal anti-ERK2 (C-14) antibodies were from Santa Cruz Biotechnology. Secondary antibodies, peroxide-conjugated swine anti-rabbit were from New England Biolabs, peroxide-conjugated sheep anti-mouse immunoglobulin from Amersham/Pharmacia, and peroxide-conjugated protein A from Kirkegaard and Perry Laboratories.

Murine fibrosarcoma cells were grown in Petri dishes (6 cm in diameter) in RPMI medium with 10% FBS up to the 80% confluence. Before starting the experiments the cells were starved for 24 h. Subsequently the cells were treated with MZ pretreated medium with or without 10% FBS for 0, 5, 30, and 60 min or with EGF (100 µg/ml) and PDGF (40 µg/ml). After the indicated time of treatment the cells were washed with PBS and scraped into ice-cold lysis buffer containing 50 mM hydroxyethylpiperazine ethane sulfonic acid, pH 7.2, 150 mM NaCl, 1 mM EDTA, 20 mM NaF, 2 mM sodium orthovanadate, 1% (w/v) Triton X-100, 10% (w/v) glycerol, and protease inhibitors (1 mM Pefabloc, 10 µg/ml leupeptin, and 1% Trasylol). Following 45 min at 4°C with gentle rocking a soluble fraction was prepared by centrifugation at 4°C for 15 min at 13,000 g. Equal amounts of cell lysates (measured by the Bradford assay) were mixed with 3× sodium dodecyl sulfate (SDS) sample buffer and heated for 2 min at 98°C. Proteins

were separated by SDS polyacrylamide gel electrophoresis and transferred onto nitrocellulose membrane. Immunoblots were blocked with 5% bovine serum albumin in TBS (10 mM Tris-HCl, pH 7.4; 150 mM NaCl) for 1 h, incubated for 1 h with primary antibodies (anti-pAkt, anti-pJNK, anti-pERK2) in TBS, washed six times for 10 min each in TBS 0.05% Triton X-100, and then incubated for 1 h with appropriate secondary antibody. Following further washes, immunoblots were visualized by using enhanced chemiluminescence reagents. To reprobe blots they were incubated in stripping buffer (62.5 mM Tris-HCl, pH 6.7; 2% SDS; 100 mM 2-mercaptoethanol) at 58°C for 25 min, washed extensively with TBS, reblocked as described above, and reblotted with the appropriate antibodies.

Isolation of apoptotic DNA fragments

HeLa cells (1×10⁵) were grown in a 10-ml flask for 24 h, after which the medium was discarded and replaced with the MZ pretreated medium (see above). After 24 h the cells were trypsinized, pelleted by centrifugation (1200 g), and washed twice in PBS. Afterwards the cells were resuspended 10 s in 100 µl lysis buffer (1% NP-40 in 20 mM EDTA, 50 mM Tris-HCl, pH 7.5) and centrifuged 5 min at 3000 g. The supernatant was transferred to a new Eppendorf tube while the pellet was incubated once more with 100 µl lysis buffer and centrifuged as before. The supernatants were pooled together and incubated 2 h in 1% SDS and RNase (5 µg/µl) at 56°C, after which the proteinase K was added in final concentration 2.5 µg/µl overnight. DNA fragments were pelleted by addition of 1/2 volume of 10 M ammonium acetate and 2.5 volume of prechilled absolute ethanol. After centrifugation (30 min, 12,000 g), the pellet was washed with 70% ethanol, centrifuged 10 min at 12000 g, dried, and dissolved in 20 µl TE buffer (10 mM Tris-HCl pH 7.4; 1 mM EDTA pH 8). The DNA was visualized on 1.5% agarose gel.

Animals

Mice

CBA/HZgr and C57BL/6 mice of both sexes were used. Toxicity study experiments were performed on the CBA/HZgr strain, while experiments with tumors were performed on both strains. For non-clinical tolerance testing male mice of the BALB/c strain were used. At the beginning of the experiments the animals were about 4 months old, weighing 25–28 g. Until beginning the experiments the mice were maintained in standard conditions with unrestricted access to food and water.

Rats

Wistar rats of both sexes from the animal breeding colony at the Institute for Medical Research, Zagreb, Croatia were used for toxicity and nonclinical tolerance testing studies. At the beginning of the experiments they were 2–3 months old, weighing in average 300 g (males) and 200 g (females).

Dogs

Twenty-two dogs were used in the experiments. They were of various breeds, weighing from 3 to 42 kg. The animals were of both sexes, 5–14 years old. The data on the 14 dogs in which disease improvement was observed, are presented in Table 2.

Application of mechanically treated natural clinoptilolite (MZ)

Because of the insolubility of the tested substance, it was administered to the animals either orally by gavage or in their diet (mice,

rats), supplemented as powder to the conventional food, or in capsules (dogs) which were again admixed to food. When testing the growth of mammary aplastic carcinoma or mammary aplastic carcinoma metastases formation MZ and standard food for laboratory mice (Pliva, Zagreb, Croatia) were mixed in the ratio 20%:80%. Each mouse on average ate about 4 g food daily, thus consuming about 800 mg MZ. When testing the growth of melanoma, MZ was given to mice orally (gavage) at doses of 20, 30, and 40 mg/mice five times per day (tested doses were 100, 150, and 200 mg/mice, respectively). In toxicity studies MZ was applied in diet mixed with standard food.

Tumors

Mammary carcinoma occurred spontaneously in CBA/HZgr mice, maintained in the animal breeding section of the Division of Molecular Medicine, Ruđer Bošković Institute, Zagreb, Croatia. The tumor is a highly anaplastic carcinoma with very high incidence of mitoses; it does not form any glandular structures and leads to spontaneous metastases in the lungs. After transplantation of 1×10^6 viable tumor cells into the animals a growing tumor is obtained which causes the mouse's death after about 4 weeks. For the purpose of the experiments tumor cell suspension was always prepared from *in vivo* growing tumor.

Melanoma B16, originally obtained from Holt Radium Institute, Manchester, United Kingdom, has been maintained at the Ruđer Bošković Institute since 1975 by subcutaneous inoculations of suspension containing 2×10^6 tumor cells into flanks of C57BL/6 mice.

Spontaneous tumors in dogs were of various origins, sizes, and locations. The data on 14 tumors are presented in Table 2. In another 8 tumors, not presented in Table 2, there were two lymphomas, two autoimmune hemolytic anemias, and one each of prostate tumor, osteosarcoma, mammary fibrochondroadenocarcinoma, and epulis.

To obtain tumor cells in suspension large pieces of tumor removed from the mice were cut up in very small pieces (Hank's solution). The particles were allowed to settle, and the supernatant (cell suspension) was removed and spun down at 150 g for 10 min. The pellet was resuspended and cell viability was tested by Trypan blue exclusion test: more than 90% of tumor cells were scored as viable. To obtain locally growing tumor, an inoculum of 0.1 ml, containing 1×10^6 viable tumor cells, was injected subcutaneously into the right thigh of recipient mice. Tumor growth was checked each day after tumor cell inoculation into the mice. When the tumor was established, its size was measured by a caliper. Three diameters were measured, and tumor volume was calculated. To obtain experimental lung metastases 0.25 ml, containing 1×10^5 mammary aplastic carcinoma cells, was injected into mouse tail vein. The mice were killed 18 days later. The lungs were removed, washed in water, separated into lobules, and immersed in a fixative. Macroscopically visible nodules on lung's surface were counted.

Toxicology studies

Preclinical toxicology was performed according to standards and regulations of the Organization for Economic Cooperation and Development principles of food laboratory practice (Paris 1998). The testing was approached by setting the "limit" test – applying the high doses of MZ, 2×200 and 2×500 mg/mouse per day orally (gavage) for 6, 14, and 30 days. Since the MZ did not cause the death of mice in a "limit" test, an "up and down" test was performed on mice, with daily doses ranging from 60 to 400 mg/mouse (MZ given orally, gavage, for 30 days). Again, no toxicity was observed. Therefore a classical acute, subchronic and chronic toxicity study of mice and rats of both sexes (separately) was performed.

Mice

The mice were of the CBA/HZgr strain. MZ was given in a diet (powdered MZ mixed with standard food at the ratio of 25:75%). The duration of study was as follows: acute toxicity, 1 month; subchronic toxicity, up to 3 months; chronic toxicity, up to 6 months. Animals were monitored for: phenotypic changes, changes in behavior, and survival (every day), changes in body weight (weekly), amount of food and water consumed (checked on days 14 and 28 when mice were kept for 24 h in metabolic cages, five mice per cage), changes in hematological and serum clinical chemistry parameters (erythrocytes, leukocytes, platelets, hematocrit, hemoglobin, glucose, alkaline phosphatase, aspartate aminotransferase, alanine aminotransferase, bilirubin, inorganic phosphorous, and calcium; after 1, 3, and 6 months); and urine clinical chemistry parameters (glucose, proteins, urobilinogen, bilirubin, nitrites, erythrocytes, leukocytes, pH, and specific gravity; urine was collected while the animals were kept, once a month for 24 h, in metabolic cages). Pathohistological analysis of liver, spleen, kidney, brain, lung, testes, ovary, duodenum, eye, stomach, large and small intestine, muscles, myocard, pancreas, thymus and axillary lymph node was carried out on killed experimental and control mice.

Rats

Wistar rats were used. MZ was given in a diet (mixed with standard food at ratios of 25:75 and 50:50). The duration of study was as follows: acute toxicity, 1 month; subchronic toxicity, 3 months; chronic toxicity, 12 months. Animals were monitored for: phenotypic changes, changes in behavior and survival (every day), changes in body weight (every 4 days), amount of food (every day) and water consumed (every 4 days), and changes in hematological and serum clinical chemistry parameters (the same as for mice; once a month). Pathohistological analysis of liver, spleen, lung, kidney, testes, ovary and brain, was performed on killed experimental and control rats after 1, 6, and 12 months.

The reproductive/developmental toxicity was tested on mice (CBA/HZgr) due to their short gestation period and larger litter size. MZ was given in a diet (powdered MZ mixed with standard food at the ratio of 25:75%). For reproductive toxicity study ten male and ten female mice were fed with the food supplemented with the MZ for 50 and at least 14 days, respectively, before mating. The treatment continued during the pre-pregnancy and pregnancy period (one cycle) and to the point of weaning offspring. The same pair of animals was fed with the MZ and monitored during four consecutive cycles (approximately 4–5 months). The same schedule was applied for control, nontreated, animals. The parental generation was monitored for duration of cycle period (pre-pregnancy and pregnancy period), fertility (presence or absence of litter in particular cycle), delivery incidence, mortality, and pathohistological appearance of ovaries, after 4th cycle. Number of total and viable pups born as well gain in pups body weight and pups mortality until weaning was also scored.

For teratology study healthy, untreated pregnant mice were fed with MZ mixed to the conventional food from day 6 through day 16 of gestation and the mice were killed 1 day before parturition. The fetuses were analyzed for microscopic pathology.

Local tolerance was evaluated to ascertain whether the test substance is tolerated at the sites in the body which may come into contact with the product as a result of its administration.

Repeated-dose dermal tolerance testing was performed on male Wistar rats and male BALB/c mice. MZ was applied on the shaved skin of the whole dorsal region of animals in three ways: (a) as original powder, (b) mixed with neutral creme at the ratio of 1:1, (c) mixed with paraffin oil at the ratio of 1:1. The animals were treated twice a day during 28 days. Macroscopic changes in the treated skin were examined daily. The left dorsal region of the animal was used as control. For microscopic analysis of the possible changes the skin samples were collected 1 day after the last treatment.

Results

Properties of mechanically treated natural clinoptilolite

Mechanically treated natural clinoptilolite (MZ) contained approximately 85 wt.% clinoptilolite. The remaining 15% consisted of silica, montmorillonite and mainly mordenite zeolite. The chemical composition of the natural clinoptilolite is presented in Table 1. Differential thermal analysis (differential thermogravimetric) of the MZ shows that the maximum rate of water desorption occurred at 50°C, indicating that the change in sample weight during heating to 50°C corresponds to the removal of loosely held moisture within the solid microstructure.

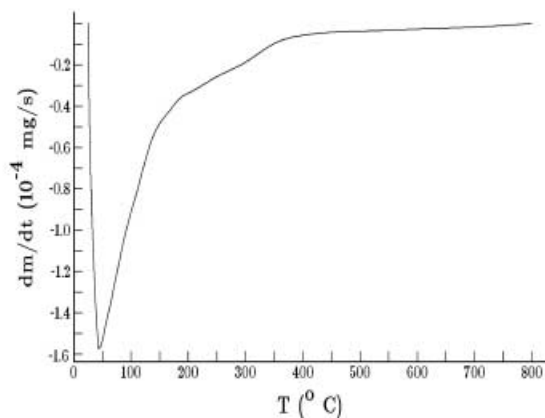
Fig. 1 **A** Differential thermogravimetric curve of MZ; dm/dt differential change (dm) in the mass of sample in differential time interval (dt); T temperature of heating. **B** Weight loss during controlled heating of the MZ from ambient temperature ($T=25^\circ\text{C}$) up to $T=800^\circ\text{C}$. **C** Distribution of differential particle sizes by number of MZ. N_D Number percentage of particles of the corresponding diameter D . **D** Cumulative particle size distribution by number of the MZ. ΣN_D Percentage of the particles having diameters between $D=0$ and D

Analysis of the water desorption curve shows that the MZ contains approx. 16 wt.% of water (loosely held moisture + zeolitic water) of which approx. 2 wt.% is loosely held moisture (Fig. 1A, B). No phase transformation was observed during the heating of MZ to 800°C . Particle size analysis of the MZ showed that maximum frequency of particles (approx. 13%) appeared at $1.5\ \mu\text{m}$ with average size of $2.9\ \mu\text{m}$. In 25% of particles the size was up to $1.5\ \mu\text{m}$, in 50% up to $2\ \mu\text{m}$, and in 75% up to $3\ \mu\text{m}$ (Fig. 1C, D).

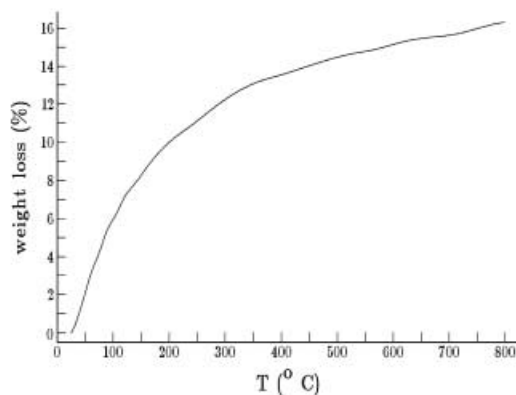
Table 1 Chemical composition of the mechanically treated natural clinoptilolite (MZ)

Oxide	wt.%
SiO ₂	50–55
Al ₂ O ₃	9.3–11.4
Fe ₂ O ₃	2.2–2.8
Na ₂ O	0.8–1.1
K ₂ O	2.9–4.3
MgO	0.8–1–2
CaO	13.7–17.2
MnO	0.07–0.90
TiO ₂	0.14–0.22
Water (800°C)	14–16

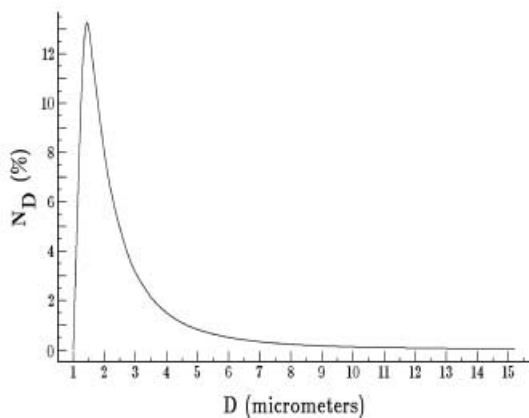
A



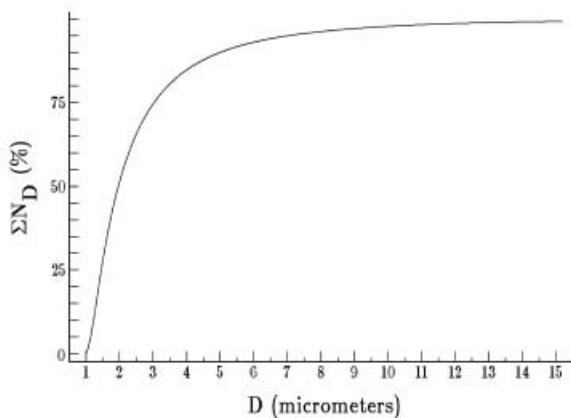
B



C



D



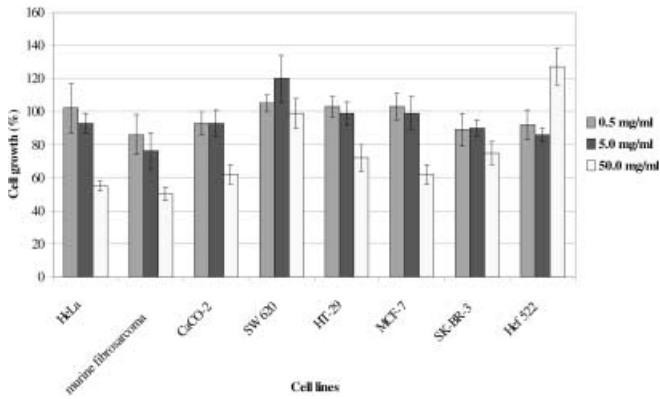


Fig. 2 Effect of the medium pretreated with 0.5, 5.0, and 50.0 mg/ml MZ on growth of various cell lines. Vertical bars Standard deviations; all white bars (50 mg/ml) are statistically different in comparison to control ($P < 0.001$, Student's *t* test)

The effect of MZ on proliferation of cell lines grown in vitro

Figure 2 presents the cell proliferation state of Hef522, HeLa, CaCo-2, SW620, HT-29, MCF-7, SKBR-3, and mouse fibrosarcoma cells after 3 days of treatment. The growth of all cell lines except Hef522 and SW620 was significantly inhibited with the dose of 50 mg/ml. The strongest inhibition (for 50%) was seen on mouse fibrosarcoma cells, the growth of SW620 cells was unchanged, and that of Hef522 cells was slightly stimulated. Similar results were observed measuring [^3H]thymidine incorporation assay in the presence of 10% FBS in mouse fibrosarcoma cells (data not shown).

Analysis of intracellular signaling pathways in MZ-treated cells

Since previous studies have indicated that exposure of cells to silicate particles leads to activation of MAPK, protein kinase C, and stress-activated protein kinases/JNK [17], we further analyzed whether MZ treatment also affects mitogenic and survival signaling pathways in these cell models.

The most significant results were detected measuring the activity of Akt protein. Akt, or protein kinase B, has been recently shown to mediate survival signals downstream of phosphoinositide-3 kinase by phosphorylating Bad proteins. We have observed an increase in Akt phosphorylation in response to serum, EGF, or insulin treatment. The addition of the MZ pretreated medium containing 10% FBS to the cells decreased Akt phosphorylation in comparison to the cells treated with only serum containing medium, while the addition of growth factors EGF and PDGF restored its activity (Fig. 3A) and overcame the effects of MZ on cell growth. Determination of the activity of Akt at various times after the addition of MZ pretreated medium with 10% FBS showed slight decrease in pAkt level after 5 min. This decrease was more

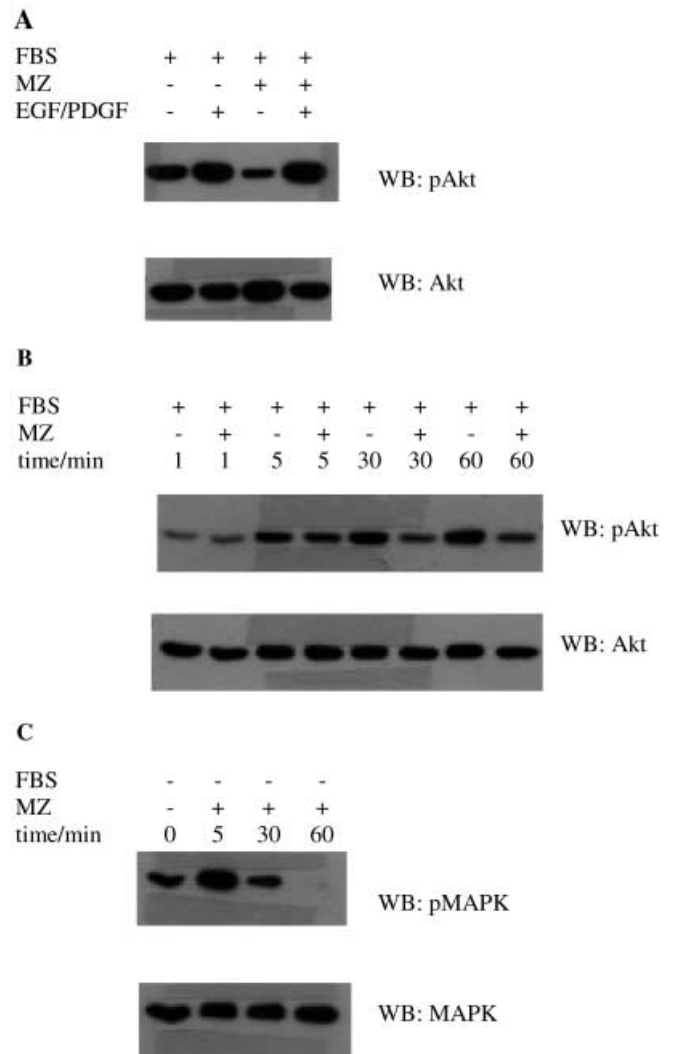
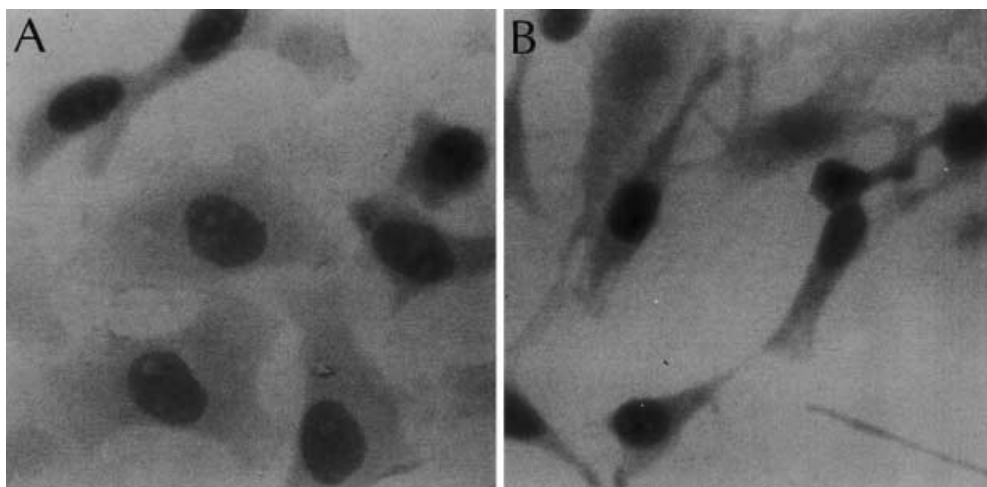


Fig. 3 **A** Activity of Akt protein 5 min after addition of the MZ pretreated medium to murine fibrosarcoma cells. **B** Decreased Akt protein activity at various times after treatment of murine fibrosarcoma cells with MZ pretreated medium. **C** Effect of serum free MZ-pretreated medium on the activity of MAPK in murine fibrosarcoma cells. WB Western blot; FBS fetal bovine serum; MZ mechanically activated clinoptilolite zeolite; pAkt phosphorylated Akt; EGF epidermal growth factor; PDGF platelet-derived growth factor; MAPK mitogen-activated protein kinase; pMAPK phosphorylated mitogen-activated protein kinase

pronounced after 30 and 60 min of treatment (Fig. 3B). However, the addition of MZ pretreated medium without serum to the cells increased activity of Akt compared only to the serum-starved cells. Overnight treatment of the cells with EGF also increased Akt activity. However, combined overnight treatment of the cells with EGF and MZ pretreated medium decreased Akt activity, indicating that inhibition of Akt might be linked to MZ inhibition of the EGF-triggered pathways.

MAP kinase activity was increased in serum-starved cells in response to EGF, PDGF, or serum. Addition of only MZ pretreated medium to the serum-starved cells increased MAPK activity only temporarily (after 5 min);

Fig. 4 Immunohistochemical analysis of p27^{KIP1} on control HeLa cells (A) and HeLa cells after incubation with the MZ pretreated medium (B). *Brown staining* Cells expressing p27^{KIP1}



in the next 30 min MAPK activity returned to the normal level (Fig. 3C). In contrast, addition of MZ pretreated medium plus 10% serum slightly decreased MAPK activity compared only to serum-treated cells or cells incubated only with MZ pretreated medium. These results are in agreement with those of the previously performed thymidine test.

Medium pretreated with MZ added to the cells either alone or in combination with serum caused no change in JNK activity (data not shown).

The effect of MZ on expression of inhibitors of cyclin-dependent kinases, p21^{WAF1/CIP1} and p27^{KIP1}, was tested using immunocytochemical method, in HeLa and CaCo-2 cells. Treatment with MZ induced the expression of p21^{WAF1/CIP1} in CaCo-2 cells and p27^{KIP1} in HeLa cells, while nontreated cells were negative for expression of p21^{WAF1/CIP1}/p27^{KIP1} (Fig. 4).

Induction of programmed cell death-apoptosis

To evaluate whether the inhibition of cell growth by MZ is due to programmed cell death, i.e., apoptosis, an attempt was made to isolate small DNA fragments. Large amount of small (degraded) DNA fragments in DNA isolate would indicate that MZ induces programmed cell death in treated cells. The result of small DNA fragment isolation from HeLa cell is shown in Fig. 5. DNA isolated from MZ treated cells exhibited significant degradation (lane 3a bulk of low-molecular, degraded DNA indicated with an arrow) in comparison to DNA from untreated cells (lane 2). The DNA degradation in MZ treated cells is most probably due to induced programmed cell death (apoptosis).

Toxicology

Oral (in diet) administration of MZ to mice and rats for 6 and 12 months, respectively, caused no changes that could be considered a toxic effect of treatment. The MZ

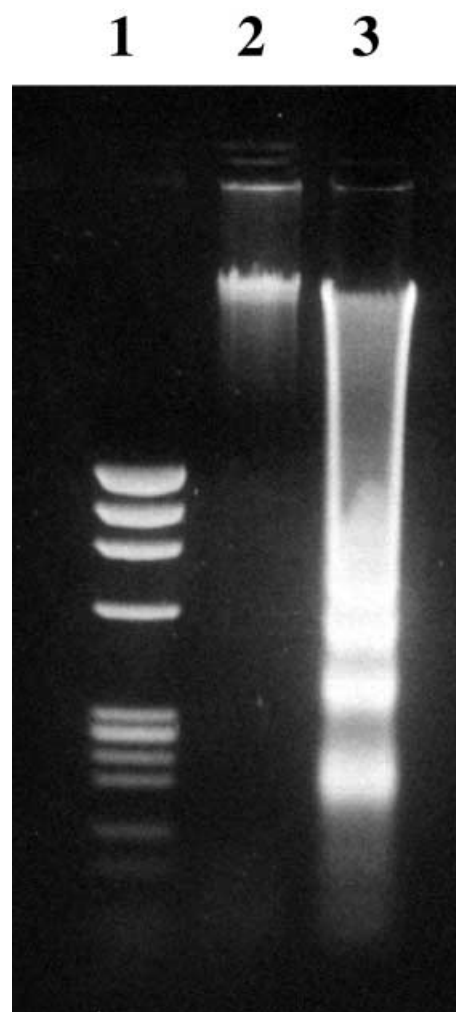


Fig. 5 Apoptotic DNA fragments in 1.5% agarose gel. *Lane 1* DNA molecular weight marker IX (Φ x 174/*Hind*III); *lane 2* DNA isolated from untreated HeLa cells; *lane 3* DNA isolated from the MZ-treated HeLa cells; degraded, low-molecular DNA fragments

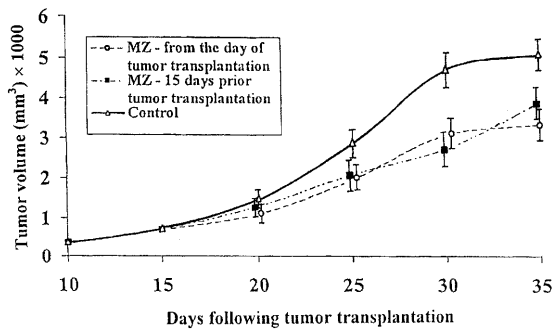


Fig. 6 Tumor growth following injection of 1×10^6 mammary aplastic carcinoma cells into the right thigh of CBA/HZgr mice. The animals were exposed to 20% of MZ in the food either from the day of tumor transplantation ($n=14$) or 15 days prior to tumor transplantation ($n=14$). Control mice received standard food. Vertical bars Standard deviation. The differences between control and both experimental groups were statistically significant ($P < 0.001$, Student's *t* test) for the days 25, 30, and 35

equalized (regulated) and shortened the prepregnancy period. The number of pups per litter was increased in MZ-treated mice. Probably for this reason the gain in pups' body weight until weaning was decreased. As a final consequence higher mortality of pups between days 8 and 21 of the neonatal period was observed. However, there are no differences between control and treated animals that would suggest reproductive toxicity attributable to the MZ administration. The MZ did not elicit toxicity during the period of organogenesis. The test substance, MZ, was not toxic or allergenic for the skin.

Effect of MZ on tumor growth in animal models

Previous studies in cultured cells have suggested that MZ inhibits growth of cancer cells in vitro. To study the effect of MZ in vivo studies on mice, rats, and dogs were undertaken. Subsequent studies were performed on murine transplantable tumors, melanoma B16, and mammary carcinoma. Mammary aplastic carcinoma cells were injected into the right thigh of two groups of mice. One group ($n=14$) was fed with food supplemented with MZ starting from 15 days prior tumor transplantation until the animal's death; the other group ($n=14$) was fed with MZ from the day of tumor transplantation until the animal's death. A group of five tumor-bearing mice receiving standard food was used as control. Tumor growth was significantly inhibited in both groups of animals fed with MZ supplemented food (Fig. 6). The tumor growth curves for individual animals were uniform, particularly when MZ was given prior to the tumor transplantation. However, there was no difference in mice survival among the groups.

Melanoma B16 cells were inoculated subcutaneously in C57BL mice on day 0. For the next 30 days the mice were given MZ orally five times per day. Tumor volume was recorded; it was markedly lower in 5 of 80 mice (daily dose 150 mg/mouse) than in the control group

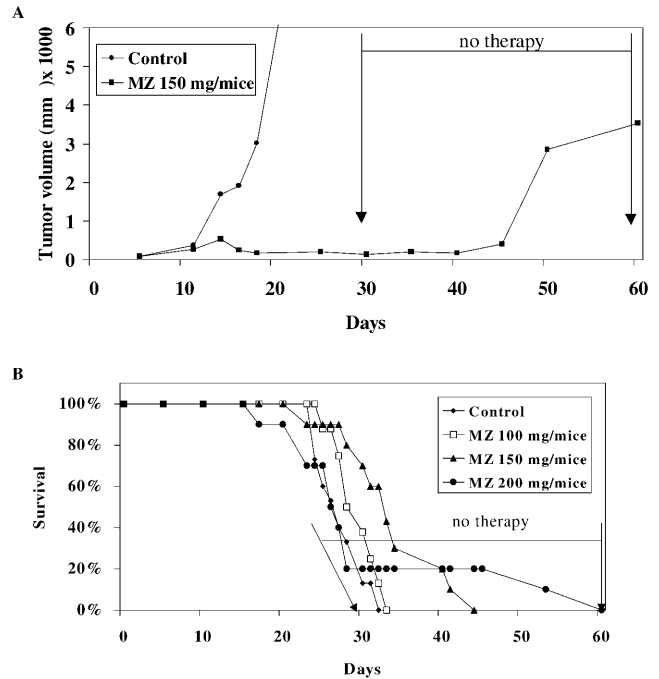


Fig. 7 Growth rate (A) of melanoma B16 treated with 150 mg MZ/mouse per day and survival (B) of melanoma-bearing mice treated with three different doses of MZ

(Fig. 7A). Despite the fact that the tumors started to grow more rapidly after the therapy with MZ was abrogated (between days 30 and 60 after tumor transplantation), the mice lived a statistically significantly longer period when treated with 200 and 150 mg MZ than control animals (Fig. 7B). The mice used for experimental mammary aplastic carcinoma lung metastases formation were fed with MZ diet from 15 days prior to tumor cell injection until to the end of the experiment, i.e., 18 days after tumor transplantation. The controls consumed standard food. Each of these two groups comprised 20 animals. About 20–40 nodules per animal were scored, but there was no difference between the groups (data not shown).

There was no effect of MZ treatment on in vivo growth of two mammary carcinomas which differed from that showed in Fig. 6 (data not shown).

Of 22 dogs suffering from various kinds of spontaneous tumors that were treated with MZ, 14 responded to therapy, i.e., the tumor disappeared completely, or the tumor size was significantly reduced (presented in Table 2). Among three dogs which had prostate tumor there was one that was stated sonography showed to have (in addition to prostate tumor) a prostate cyst (case 3). The dog was conspicuously quiet, without appetite, and hardly moved. When the usual therapy did not work, MZ therapy was started. After only 2 days of treatment the dog became active; on the third day it began eating normally, and on the fourth day the dog urinated normally, blood-free urine. On day 10 the cyst and the tumor were reduced in size, and after 1 month they had disappeared completely. Although the prostate be-

Table 2 The effect of MZ treatment on growth of spontaneous tumors of dogs (→ values before and after treatment with MZ, *a.t.* after beginning of treatment, *HMT* hematocrit, *ALT* alanine aminotransferase, *AST* aspartate aminotransferase, *ALP* alkaline phosphatase, *GGT* γ -glutamyl transferase, *L* number of leukocytes)

No.	Breed	Age (years) ^a	Weight (kg)	Sex	Diagnosis	Previous treatment	MZ treatment	Biochemical and hematological changes	Therapeutic effects
1	Schnauzer	8	15	M	Prostate adenocarcinoma ^b	Castration	3×200 mg/day, 28 days	HMT 61→45; ALT 103→62	7 days a.t. general improvement; withdraw of catheter; 14 days a.t. no signs of disease
2	Poodle	12	16	M	Prostate adenocarcinoma (4×3 cm) and testis tumor (20 cm)	–	3×200 and 2×200 mg/day, 6 months	AST 55→10; GGT 4→1	90 days a.t. reduction in tumor mass (testis) to 1/3
3	German shepherd	8	42	M	Prostate adenocarcinoma (5×5 cm) and cyst	Antibiotics	3×1200 mg/day	Bilirubin 25.8→6.2; AST 497→16; ALT 433→43; ALP 79→33	29 days a.t. tumor disappeared
4	Mixed German shepherd	14	20	F	Mammary adenocarcinoma, multiple – 5 nodes (0.5–3 cm)	–	3×400 mg/day, 1 month	No changes	10 days a.t. all nodes disappeared; 12 months later no signs of disease
5	English cocker spaniel	8	15	F	Mammary adenocarcinoma, multiple – 4 nodes (0.5–3 cm)	–	3×400 mg/day, 58 days	No changes	58 days a.t. all tumor nodes reduced in size 50%
6	Poodle	11		F	Mammary adenocarcinoma, multiple – 4 nodes (0.5–3 cm)	–	3×400 mg/day, 2.5 months	No changes	2–3 months (smaller nodules); 4–6 months (larger nodules)
7	Dobermann pinscher	8		F	Mammary adenocarcinoma, multiple – 4 nodes (0.5–3 cm)	–	5×400 mg/day, 3 months	No changes	2–3 months (smaller nodules); 4–6 months (larger nodules)
8	English cocker spaniel	9		F	Mammary adenocarcinoma, multiple – 4 nodes (0.5–3 cm)	–	3×400 mg/day, 4 months	No changes	2–3 months (smaller nodules); 4–6 months (larger nodules)
9	Airedale terrier	9		F	Mammary adenocarcinoma, multiple – 4 nodes (0.5–3 cm)	Antibiotics	5×400 mg/day, 10 months	No changes	2–3 months (smaller nodules); 4–6 months (larger nodules)
10	German shepherd	8	38	M	Skin adenocarcinoma (tail)	Surgically removed, resection wound did not heal	6×400 mg/day, 62 days, and local appl. of powdered substance	Glucose 6.9→3.8; AST 50→38	3 days a.t. normal healing started and completed 7 days later

Table 2 (continued)

No.	Breed	Age (years) ^a	Weight (kg)	Sex	Diagnosis	Previous treatment	MZ treatment	Biochemical and hematological changes	Therapeutic effects
11	Mixed German shepherd	10	35	M	Carcinoma planocellulare of the skin (tail), 3 tumor	Two nodes surgically removed	4×100 mg/day, 93 days	Urea 17.5→6.3	remaining node disappeared 67 days a.t.
12	Malamute	12	40	M	Carcinoma planocellulare of the tongue	Surgically removed, resection wound did not heal	3×100 mg/day, 32 days	–	3 days after treatment wound started to heal, and 2 days later no further signs of wound visible; dog started to eat
13	German pinch	5	3	M	Hypertrophy and hyperplasia of salivary gland	Antibiotics	3×100 mg/day, 147 days	Urea 9.5→7.5; AST 40→27; ALT 54→36; L 3.1→12	7 days a.t. node became softer and smaller (75%); 14 days later no signs of hypertrophy
14	Berner sennenhund	8	40	M	Lung cancer	–	4×400 mg/day, 35 days	AST 35→16; bilirubin 8.5→2.8	7 days a.t. general improvement; 7 days later no signs of tumor (obtained by X-ray)

^a At the beginning of therapy

^b Hormone dependent

came only insignificantly smaller, the dog showed no signs of illness. At this point it is interesting to note that the very high pretherapy serum values for aspartate aminotransferase (497 $\mu\text{mol/l}$) and alanine aminotransferase (433 $\mu\text{mol/l}$) decreased after 1 month of MZ therapy to normal levels (16 and 43 $\mu\text{mol/l}$) and remained in the normal range for entire observation period (5 months).

Another dog (case 2) had, in addition to prostate tumor, a testis tumor. The testis was approximately 20 cm in diameter when the therapy with MZ was started. After 1 month therapy the testis size was reduced by one-third. After 2 months of therapy the testis was reduced in size to one-half and after 3 months to one-third of its pre-treatment size (Fig. 8A). However, the prostate remained equally large.

The third dog (case 1) diagnosed to have prostate adenocarcinoma came to the clinic in a very bad general condition. It urinated only with great difficulty. After 1 month of classical therapy no improvement was observed. A catheter was placed in the dog's urethra. The therapy was continued for a further 2 weeks but did not work. The dog was *ante finem* and the owners asked for euthanasia. Classical therapy was then replaced by MZ

therapy (3×200 mg/day). After 1 week a general improvement was observed, and the catheter was removed. After 14 days of therapy no signs of disease were still visible. The therapy continued for an additional 14 days, with daily health improvement. Then the owners decided on castration (in most cases castration eliminates problems related to the prostate), and the therapy with MZ was stopped. Eight months later the dog is still alive without any major health problems.

Three dogs suffered from skin tumors. One of these (case 11) had three lesions nodules on the skin above the tail. Two were removed, and the third, the smallest, was left. Histologically the tumor was diagnosed as carcinoma planocellulare. After 1 month of therapy with MZ the cherry-sized tumor was reduced in size by one-third. Over following 5 weeks the lesion disappeared completely. The dog is still (7 months latter) under therapy. The presently 11-year-old dog is very vivacious and in unusually good condition.

Another dog (case 10) suffered from adenocarcinoma on the skin of the tail, which was surgically removed. However, even 2 weeks after surgery the wound did not heal, and amputation was considered. The dog was then

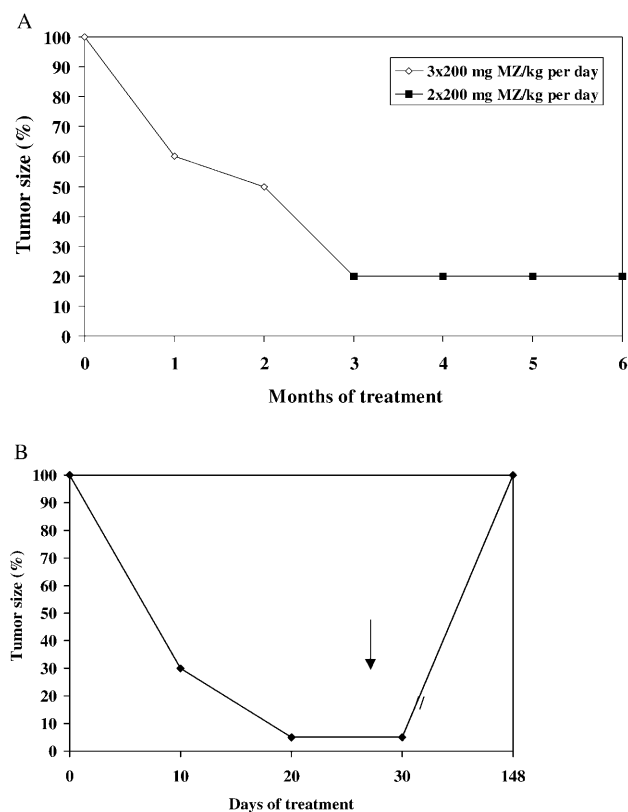


Fig. 8 Growth rate of testicular tumor (A) and salivary gland hyperplasia (B) in dogs. **A** Poodle, 12 years old, case 2. **B** Pinch, 5 years old, case 13. *Arrow* Day of therapy cessation. All other details are indicated in Table 1

given MZ in capsules, and powdered MZ was also scattered on the wound. The wound healed within 1 week.

The third dog (case 12) had a growth on its tongue of approx. 2 cm diameter. Histologically it was carcinoma planocellulare. After surgical removal of the tumor the wound did not heal. The dog was given MZ orally in capsules, and powdered MZ was also applied locally. Five days later the biopsy wound was no longer visible.

A 5-year-old dog (case 13), diagnosed to have enlarged (walnut-size node) left salivary gland, was treated with conventional therapy for 4 months, without success. During that time the gland become larger and larger, and the dog developed serious problems with swallowing and salivation. After only 1 week of MZ therapy the node become softer and smaller by one-third. After a further 1 week the node disappeared completely, and only the capsule was palpable (Fig. 8B).

Mammary adenocarcinomas, in the form of multiple nodules (in sizes between that of green beans and large walnuts), were diagnosed in six female dogs. After the therapy with MZ was started, the nodules disappeared completely: in one dog after 10 days, with no signs of disease even after 12 months; in four dogs after 2–3 months (smaller nodules) and 4–6 months (larger nodules), with no signs of disease thereafter, at the present, 2 months; and in one dog the nodules were reduced in size to 50% after 58 days of treatment.

In one case of a dog (case 14) with lung cancer, again, after only 14 days of treatment with MZ (4×400 mg/day) signs of tumor disappeared completely.

In addition to the effects of MZ expressed on the primary disease, all dogs, even those in which primary disease was not cured, responded to MZ therapy in only about 7 days with general constitutional and behavioral improvement lasting even after the therapy was interrupted. The same was observed for some hematological and serum clinical parameters measured before and after the therapy. Hematocrit decreased to the normal range in case 1. Very high total serum bilirubin values fell to the normal range in cases 3 and 14, while serum urea concentration change was noted in cases 11 and 13. The most pronounced improvement was noted for aspartate aminotransferase, alanine aminotransferase, and alkaline leukocyte phosphatase, with pretherapy values normalized after the therapy was started in almost all cases (nos. 1, 2, 3, 10, 13, and 14; Table 2).

Discussion

Numerous natural compounds are commonly used for the treatment of various diseases, including green tea and soybean extracts (for review see [20]). Recent findings indicate that dietetic products and antioxidant compounds also have a beneficial effect particularly in cancer patients. In many cases the exact mechanism of their action is not fully understood. In this report we studied the effect of natural clinoptilolite zeolite particles on development of several cancer models in vivo and in vitro. We found that mechanically activated clinoptilolite zeolites act as anticancer therapeutic agents in in vivo animal studies and in tissue culture cell models. Clinoptilolite applied orally in mice and dogs suffering from a variety of tumor types led to a significant shrinkage of some tumors and improvement in overall health status in some animals.

The range of effects was diverse, ranging from negative antitumor response, to normalization of biochemical parameters, prolongation of life span, and decrease in tumor size. The best results in animal models were observed in the treatment of skin cancer in dogs, suggesting that adsorption of some active components is responsible for MZ activity (direct contact action). Complementary studies performed in tissue culture indicated that MZ treatment affects proliferation and survival of several cancer cell lines. Addition of MZ inhibited cell proliferation in a concentration-dependent manner, in part due to induction of inhibitors of cycline dependent kinases, inhibition of B/Akt expression and induction of programmed cell death.

The work described here was performed with the non-toxic natural, high silica content zeolite, clinoptilolite. The zeolite particles were negatively charged in the entire pH range studied (pH 1–11). Electron microscopy showed the absence of fibers, and most particles were round with very rough surface (data not shown). The ab-

sence of fibrous, positively charged particles was encouraging since such particles are present in asbestos and erionite zeolites, which are highly carcinogenic and mutagenic. In addition, activated zeolite particles did not catalyze the production of hydroxyl radicals, unlike asbestos or erionite (data not shown). It seems that absence of fibrous particles capable of producing hydroxyl radicals makes this zeolite sample nontoxic and noncarcinogenic, at least when applied orally.

Silicate and aluminosilicate particulates can interact directly with specific cells and modify their intracellular pathways, leading to the regulation of gene expression. MZ was particularly successful in inhibiting protein kinase B/Akt in *in vitro* experiments with cancer cells. Such inactivation resulted in growth inhibition and increase in apoptosis of cancer cells. Inhibition of Akt by MZ treatment was shown only in the presence of serum. This indicated that adsorption of serum components can be one of the mechanisms of MZ action in these experiments. Indeed, the addition of EGF to serum-free medium led to activation of Akt, which was also blocked by MZ pretreatment. Adsorption of molecules involved in signal transduction cascades, such as inositol phosphatides and calcium, might also contribute to its therapeutic efficiency. Preliminary lipid adsorption studies show that MZ are strong lipid sorbents. Similar results are observed with adsorption of proteins. Modifications of membrane ordering and interactions of other proteins with membrane proteins might also be involved [21], since membrane translocation is needed for activation of protein kinase B/Akt. It has also recently been shown that the activation of phosphoinositide-3 kinase and Akt is responsible for the ability of transformed epithelial cells to survive without cell attachment. Recent results indicate that constitutive activation of phosphoinositide-3 kinase in five small-cell lung cancers cell lines studied was responsible for fast growth and anchorage independence of small-cell lung cancer cells [22]. In accordance with this, MZ treatment leads to inhibition of protein kinase B/Akt pathways and subsequent apoptosis in our cell model. Akt has recently been demonstrated to inactivate an important cyclin inhibitor and tumor suppressor molecule, p27^{KIP1} [22].

Here we provide evidence that MZ treatment increases levels of p21^{WAF1/CIP1} and p27^{KIP1} in tumor cell models. It is not yet clear whether inhibition of Akt is involved in regulation of expression of p21^{WAF1/CIP1} and p27^{KIP1} cell cycle inhibitors. Preliminary results also show that MZ adsorbs and deactivates nitric oxide and other oxidants. In addition, it has recently been reported that antioxidants stimulate the activation of cyclin inhibitor p21^{WAF1/CIP1} [23]. This molecule is responsible for the arrest of cell growth, and its expression in adenocarcinomas of lung is positively correlated with optimistic survival prognosis. The present study observed that activated clinoptilolite induces tumor suppressor molecules (both p21 and p27).

The mechanisms of action of MZ *in vivo* remain largely unknown at this time. The results presented here

indicate that inhibition of proliferation and survival of cancer cells may be part of mechanisms involved in anti-cancer effect of MZ compounds. More studies on several other aspects of their action including possible immunomodulatory action of MZ will be performed in the future. Taken together, this report characterizes cellular effects of the MZ compounds in tissue culture cell models and provides data supporting a role of natural zeolite as an anticancer therapeutic agent in *in vivo* tumor models.

References

- Breck DW (1964) Crystalline molecular sieves. *J Chem Educ* 41:678–689
- Flanigen EM (1980) Molecular sieve zeolite technology—the first twenty-five years. In: Rees LVC (ed) *Proceedings of the 5th International Conference on Zeolites*. Heyden, London, pp 760–780
- Sersale R (1985) Natural zeolites: processing, present and possible applications. *Stud Surface Sci Catalysis* 24:503–512
- Naber JE, De Jong KP, Stork WHJ, Kuipers HPCE, Post MFM (1994) Industrial application of zeolite catalysis. *Stud Surface Sci Catalysis* 84C:2197–2220
- Garces JM (1999) Observations on zeolite applications. In: Treacz MMJ, Marcus BK, Misher ME, Higgins JB (eds) *Proceedings of the 12th International Conference on Zeolites*. Materials Research Society, Warrendale, pp 551–566
- Colella C (1999) Natural zeolites in environmentally friendly processes and applications. *Stud Surface Sci Catalysis* 125: 641–655
- Bedioui F (1995) Zeolite-encapsulated and clay-intercalated metal porphyrin, phthalocyanine and Schiff-base complexes as models for biomimetic oxidation catalysts: an overview. *Coordination Chem Rev* 144:39–68
- Concepcion-Rosabal B, Rodriguez-Fuentes G, Simon-Carballo R (1997) Development and featuring of the zeolitic active principle FZ: a glucose adsorbent. *Zeolites* 19:47–50
- Rodriguez-Fuentes G, Barrios MA, Iraizoz A, Perdomo I, Cedre B (1997) Enterex – anti-diarrheic drug based on purified natural clinoptilolite. *Zeolites* 19:441–448
- Ueki A, Yamaguchi M, Ueki H, Watanabe Y, Ohsawa G, Kinugawa K, Kawakami Y, Hyodoh F (1994) Polyclonal human T-cell activation by silicate *in vitro*. *Immunology* 82: 332–335
- Aikoh T, Tomokuni A, Matsukii T, Hyodoh F, Ueki H, Otsuki T, Ueki A (1998) Activation-induced cell death in human peripheral blood lymphocytes after stimulation with silicate *in vitro*. *Int J Oncol* 12:1355–1359
- Drumm K, Oettinger R, Smolarski R, Bay M, Kienast K (1998) *In vitro* study of human alveolar macrophages inflammatory mediator transcriptions and releases induced by soot FR 101, Printex 90, titaniumdioxide and Chrysotile B. *Eur J Med Res* 3:432–438
- Holian A, Uthman MO, Goltsova T, Brown SD, Hamilton RF (1997) Asbestos and silica-induced changes in human alveolar macrophage phenotype. *Environ Health Perspect* 105 [Suppl 5]: 1139–1142
- Schimmelpfeng J, Seidel A (1991) Cytotoxic effects of quartz and chrysotile asbestos: *in vitro* interspecies comparison with alveolar macrophages. *J Toxicol Environ Health* 33:131–140
- Allison AC, Harrington JS, Birbeck M (1966) An examination of the cytotoxic effects of silica on macrophages. *J Exp Med* 124:141–154
- Tsuda T, Morimoto Y, Yamato H, Nakamura H, Hori H, Nagata N, Kido M, Higashi T, Tanaka I (1997) Effects of mineral fibers on the expression of genes whose products may play a role in fiber pathogenesis. *Environ Health Perspect* 105 [Suppl 5]:1173–1178

17. Lim Y, Kim SH, Kim KA, Oh MW, Lee KH (1997) Involvement of protein kinase C, phospholipase C, and protein tyrosine kinase pathways in oxygen radical generation by asbestos-stimulated alveolar macrophages. *Environ Health Perspect* 105 [Suppl 5]:1325–1327
18. Simeonova P, Torium W, Kommineni C, Erkan M, Muson AE, Rom WN, Luster MI (1997) Molecular regulation of IL-6 activation by asbestos in lung epithelial cells-role of reactive oxygen species. *J Immunol* 159:3921–3928
19. Martin LD, Krunkosky TM, Dye JA, Fischer BM, Jiang NF, Rochelle LG, Akley NJ, Dreher KL, Adler KB (1997) The role of reactive oxygen and nitrogen species in the response of airway epithelium to particulates. *Environ Health Perspect* 105 [Suppl 5]:1301–1307
20. Čolić M, Pavelić K (2000) Molecular mechanisms of anticancer activity of some natural dietetic products. *J Mol Med* 78:333–336
21. Peterson MW, Kirschbaum J (1998) Asbestos-induced lung epithelial permeability: potential role of nonoxidant pathways. *Am J Physiol* 19:L262–L268
22. Moore SM, Rintoul RC, Walker R, Chilvers ER, Haslett C, Sethi T (1998) The presence of a constitutively active phosphoinositide 3-kinase in small cell lung cancer cells mediates anchorage-independent proliferation via a protein kinase B and p70^{s6k}-dependent pathway. *Cancer Res* 58:5239–5247
23. Chinery R, Brockman JA, Peeler MO, Shyr Y, Beauchamp RD, Coffey RJ (1997) Antioxidants enhance the cytotoxicity of chemotherapeutic agents in colorectal cancer-a p53 independent induction of p21^{WAF1/CIP1} via C/EBP β . *Nat Med* 3:1233–1241